



FOCUSING ON TUMORS

# *Ependymoma*



American Brain Tumor Association

# *A Word About ABTA*

Founded in 1973, the not-for-profit **American Brain Tumor Association** has a proud history of funding research, providing patient services, and educating people about brain tumors. Our mission is to eliminate brain tumors through research and to meet the needs of brain tumor patients and their families.

We gratefully acknowledge Regina Jakacki, MD, Director, Pediatric Neuro-Oncology Program, Children's Hospital of Pittsburgh, Pittsburgh, Pennsylvania for this edition of "*Ependymoma*." We also thank Beverly LaVally, RN of the Dana-Farber Cancer Institute, Boston for coordinating the original edition of this publication.

This publication was made possible through the generosity of International Profit Associates.

ISBN 0-944093-74-4

COPYRIGHT © 1990, 1995, 2001, 2006 ABTA

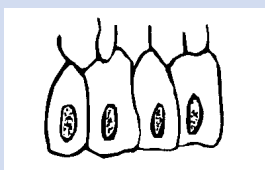
REPRODUCTION WITHOUT PRIOR WRITTEN PERMISSION IS PROHIBITED.

# Introduction

Any tumor that arises from the glial, or supportive, tissue of the brain is called a “glioma.” One type of glioma is the ependymoma. Ependymomas arise from ependymal cells which line the ventricles of the brain and the center of the spinal cord. Occasionally, ependymal cells are found within the brain itself. Ependymomas are soft, greyish or red tumors which may contain cysts or mineral calcifications.

## EPENDYMAL CELLS

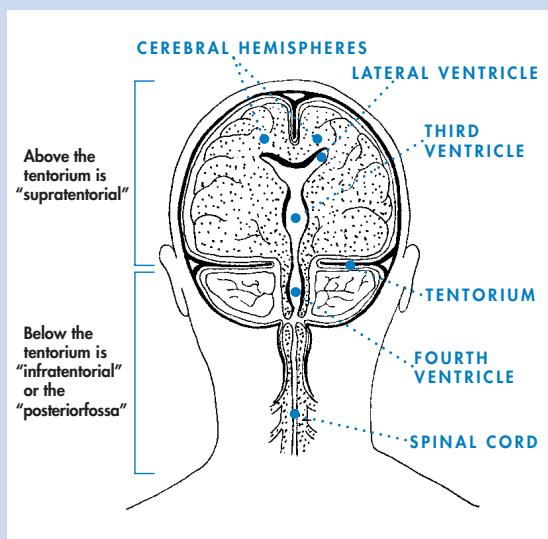
Ependymal cells line the ventricles of the brain and the center of the spinal cord.



The words “supratentorial” and “infratentorial” describe the location of the ependymoma within the brain. The tentorium is a thick membrane which separates the top two-thirds of the brain from the bottom third. Supratentorial ependymomas occur *above* the tentorium. This area includes the cerebral hemispheres, the lateral and the third ventricles. Infratentorial ependymomas occur *below* the tentorium. This area, also called the posterior fossa, includes the fourth ventricle, the brainstem and the cerebellum.

There are four major types of ependymomas: *myxopapillary ependymomas*, *subependymomas*, *ependymomas* and *anaplastic ependymomas*. Many pathologists also assign a number “grade” to ependymomas. The grade is based on how much the cells look like normal ependymal cells, although various grading systems exist. The cells of a grade I tumor look somewhat unusual, whereas grade III tumor cells look definitely abnormal.

## THE TENTORIUM



Most grade I tumors do not recur after complete surgical removal. Grades II and III tumors need additional treatment and have a higher likelihood of recurring.

Myxopapillary ependymomas tend to occur in the lower part of the spinal column. Subependymomas usually occur near a ventricle. Both are slow growing, and are considered to be low-grade or grade I tumors.

Ependymomas are the most common of the ependymal tumors, and are considered grade II tumors. These tumors are usually located along the ventricular system, often in the posterior fossa or in the spinal cord.

Anaplastic ependymomas are high-grade tumors (grade III) and tend to be faster growing than the low-grade tumors. They usually occur in the posterior fossa.

## *Incidence*

Ependymomas are relatively rare tumors, accounting for 3-6% of all primary brain tumors. However, they are the third most common brain tumor in children. About 30% of pediatric ependymomas are diagnosed in children younger than 3 years of age.

The location of ependymomas in adults tends to be different than the location of ependymomas in children. In adults, 60% of these tumors are found in the spinal cord. In children, 90% of ependymomas are found in the brain, with the majority located in the posterior fossa.

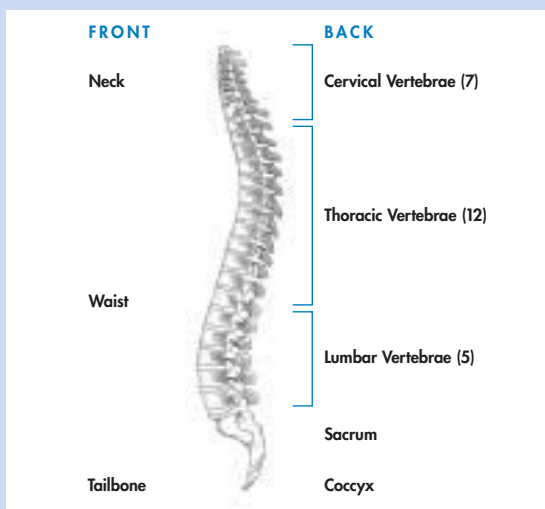
## *Cause*

The cause of ependymomas, like that of other brain tumors, is unknown. It is uncertain whether viruses (e.g. SV40) play a role in the development of ependymomas. Much more research is necessary to determine whether this is indeed a factor in humans, since these particular viruses do not normally affect humans.

## *Symptoms*

Symptoms of an ependymoma are related to the location and size of the tumor. In neonates and infants, enlargement of the head may be one of the first symptoms. Irritability, sleepiness and vomiting may develop as the tumor grows. In older children and adults, nausea, vomiting and headache are the most common symptoms. These are usually signs of increased pressure, which may develop if the tumor blocks the drainage of cerebrospinal fluid (the liquid that bathes the brain).

## SPINE



Headaches are a common symptom, and are generally worse in the morning. A tumor near the brainstem may cause one or both eyes to cross, balance problems, or trouble walking. Neck pain may result from a tumor growing near the brainstem or the upper part of the spinal cord. Seizures, headaches and weakness of one side or one part of the body may occur with a tumor in the cerebral hemispheres.

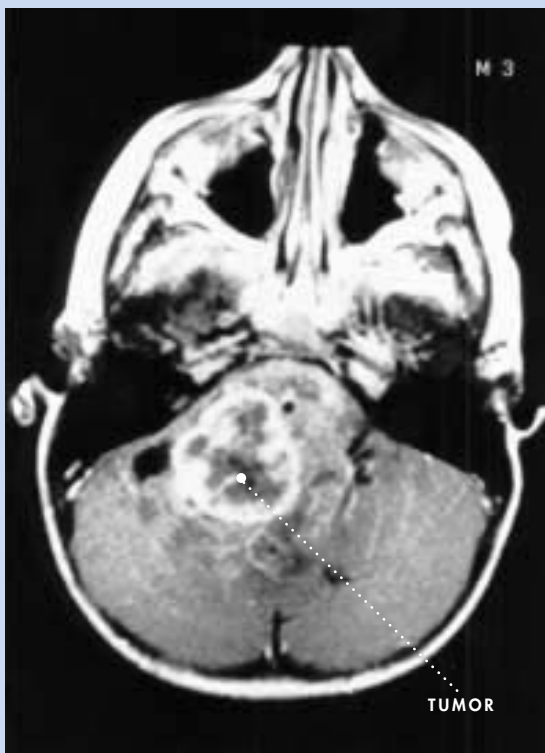Spinal cord tumors often cause leg or back pain which can be severe enough to awaken the person from sleep. Tingling sensations, numbness, or weakness in the arms or legs may occur with increasing frequency. Difficulty with bladder or bowel control may be caused by an ependymoma in the lower part of the spine.

If you would like to know more about the symptoms of brain tumors, please visit our web site at [www.abta.org](http://www.abta.org).

## Diagnosis

Magnetic Resonance Imaging (MRI) scans and/or Computerized Axial Tomography (CT) scans are required for patients suspected of having a brain tumor. The MRI, which uses radio waves and a magnetic field, provides details about the location of the tumor and which parts of the brain or spinal cord are involved prior to surgery. CT scanners are sophisticated x-ray devices connected to computers. CT scans are useful for assessing hydrocephalus (the buildup of cerebrospinal fluid in the brain). However, only microscopic examination of a sample of tissue obtained during surgery or biopsy confirms the exact diagnosis.

MRI SCAN OF AN EPENDYMOMA



MRI courtesy of Dr. Jakacki

About 10-15% of ependymomas spread, or metastasize, through the cerebrospinal fluid. The tumor cells then may grow independently, in or along the spinal cord, or rarely, in other places in the brain. Infratentorial tumors are more likely to spread to the spine than supratentorial tumors. Ependymomas almost never spread outside of the brain and spinal cord.

A spinal MRI scan and lumbar puncture (spinal tap) will be performed to determine whether the tumor has spread to the spine. The fluid obtained during the spinal tap will be tested for the presence of tumor cells. Your doctor will decide the appropriate time to perform these tests. The results are used to guide treatment.

## *Treatment*

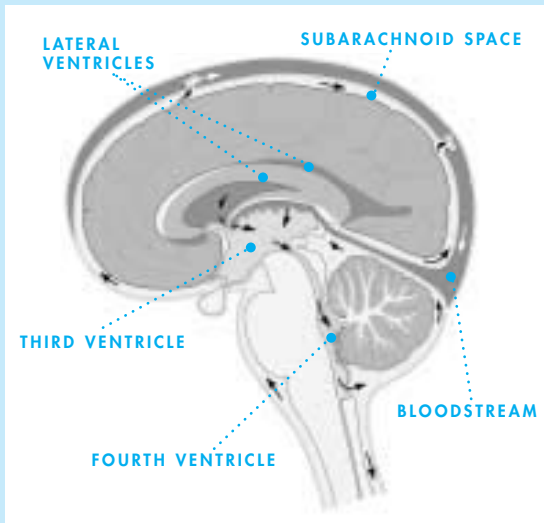
The treatment of an ependymoma varies depending on its location, grade, and whether the tumor has spread to the spine.

### **SURGERY**

The most important step in the treatment of an ependymoma is surgery to remove as much tumor as possible. Studies clearly show that patients whose tumor can be “grossly” removed (removing all tumor that can be seen) have the best chance of long-term survival. The amount of tumor that can be removed, however, depends on the location of the tumor.

High-powered microscopes in the operating room help the surgeon see tumor located in and around the ventricles or the brainstem. Removal of all visible tumor is not always possible, especially if the tumor is attached to the brainstem or involves other important areas of the brain. In children, ependymomas often fill the fourth ventricle and extend through its floor into the brainstem, making safe removal of those sections of tumor difficult.

## CEREBROSPINAL FLUID FLOW



Hydrocephalus is often present at the time of diagnosis if the tumor has blocked the out-flow of cerebrospinal fluid. Tumor removal may open these fluid pathways, although some patients will still require the placement of a ventriculoperitoneal (VP) shunt to by-pass the blockage. Many surgeons will place a temporary external ventricular drain during surgery. This is used to drain off excess fluid for a few days after the surgery. If it cannot be removed after a few days, a permanent shunt may be required.

An MRI of the brain should be done within a day or two of surgery to determine how much visible tumor remains, if any.

## RADIATION

Radiation therapy is usually recommended for older children and adults following surgery, even if all visible tumor was removed. Patients treated with radiation therapy following surgery generally have a better chance of long-term survival than patients treated with surgery alone.

The age of the patient, the location of the tumor, how easily it was removed, and whether it has spread are considered in treatment planning. If the tumor is localized, radiation therapy is usually given just to that area of the brain. If the tumor has spread, radiation is usually given to the entire brain and spine, with an extra amount of radiation (called a boost) given to the area of the brain where the tumor started.

There are different methods of administering radiation. Conventional external beam radiation is given 5 days a week for 6 weeks. Conformal-beam radiation therapy contours the radiation beams to the shape of the tumor. Radiosurgery is a way of giving a high-dose of precisely focused radiation to the tumor. This is most commonly used for ependymomas that grow back after conventional radiation. Your doctor will decide which form of radiation is best for you.

Because of the long-term side effects of radiating young children, chemotherapy may be used to delay radiation therapy in the very young child. If the tumor grows despite the chemotherapy, radiation therapy may be considered.

## **CHEMOTHERAPY**

Chemotherapy uses special drugs to kill tumor cells. But its role in the treatment of newly diagnosed ependymoma is not clear at this time. Some tumors respond to treatment for awhile, while others continue to grow. Chemotherapy may also be used to delay radiation for infants and young children, or to treat tumors that have grown back after radiation therapy. Treatment studies using either cisplatin or carboplatin alone or in combination with other chemotherapy drugs have shown the best results — about half of the tumors shrink in size, although not usually for a long time.

## TO LEARN MORE

With improved neurosurgical and radiation therapy techniques, patients with ependymomas have a significantly increased chance of survival, particularly if they are cared for by an experienced multi-disciplinary team of medical professionals at an established pediatric or adult cancer center.

Additional treatment information about this tumor is available from the National Cancer Institute's Cancer Information Service at 800-422-6237. Choose the option of speaking to an information specialist. CIS can provide information about ependymomas in adults or children, and a list of clinical trials (investigative new treatments) open to those with an ependymoma. Be sure to share the information you find with your healthcare team. They can advise you about the benefits and risks of the treatments based on your individual tumor.

We maintain a listing of physicians involved in clinical trials, and extensive resources for support services. We can be reached at 800-886-2282.

## *Treatment Side Effects*

Some treatment, while increasing survival, may have significant side effects on children. Prior to treatment your child may undergo neuropsychological testing. Those results can be used as a baseline for future evaluations.

Surgery, particularly for infratentorial ependymomas, may result in the development or temporary worsening of balance, speech, or swallowing difficulties. Most of these changes will improve over several weeks or months.

The effects of radiation therapy to the brain are of great concern to those who treat children

with brain tumors. A significant number of children, particularly those who are less than 3 years old at the time of treatment, experience some degree of decreased intellect and learning problems following radiation to large areas of the brain. The extent of the learning problems is correlated with the amount of brain radiated and the age of the child. Radiation to just the back part of the brain does not cause as many problems as to the upper part of the brain. When the upper part of the brain is radiated, teachers and parents often report significant problems with reading, writing, and short term memory. The role of special education programs to help these children develop their strengths and identify their weaknesses is of prime importance. Older children and adults tend to have fewer problems. Poor growth may be a consequence of radiation therapy damage to the hypothalamus or pituitary gland which produce several important hormones. Replacement of these hormones is often necessary, under the supervision of a pediatric endocrinologist. Radiation to the spine at a young age may also cause shortened stature. Weakening of the muscles next to the spine is possible, also.

The long-term effects of chemotherapy in children are still being studied. Platinum-based drugs often cause hearing loss, as can radiation therapy when delivered near the ears. Both radiation and chemotherapy can increase the chances of developing a second cancer or brain tumor. Infertility can be caused by chemotherapy.

**The risk of incurring long term side effects due to treatment must be weighed against the outcome if these therapies are not administered. Your doctor can help you look at these concerns and understand the risks based on your child's particular treatment plan, as well as help you balance the benefits of therapy against the potential risks.**

## Follow-up

MRI scanning of the brain and/or spinal cord is usually done every 3-4 months for the first two years following diagnosis. These scans are used to determine the effectiveness of treatment and to watch for possible recurrence. Scans are done less frequently thereafter, unless symptoms develop which might indicate tumor growth. Your doctor will determine the appropriate schedule.

## Recurrence

The extent of tumor removal continues to be the strongest factor influencing recurrence and survival. Age at diagnosis, amount of tumor remaining after surgery, whether the tumor has spread, and the therapy given can all contribute to outcome. Researchers are also studying the biologic features of these tumors to determine which may be useful in predicting prognosis.

For patients whose tumors recur after initial treatment, re-operation when possible, followed by additional therapy, can be helpful. Newer investigational treatments include various forms of chemotherapy, and re-irradiation (possibly with radiosurgery) to the site of tumor recurrence.

## A Next Step

Our web site — [www.abta.org](http://www.abta.org) — offers extensive brain tumor information, treatment and research updates, patient/survivor/family stories, and a separate section for children called ABTA Kids. A pen-pal program, Connections, links people interested in this disease with others. Parent/teacher education packets help ease your child's return to their classroom. *Alex's Journey* is a fiction story of a child with a brain tumor. Available in VHS or DVD format, this short movie is appropriate for a child with a brain



# Publications & Services

## **BUILDING KNOWLEDGE**

Dictionary for Brain Tumor Patients  
Living with a Brain Tumor  
A Primer of Brain Tumors

## **FOCUSING ON TUMORS**

Ependymoma  
Glioblastoma Multiforme and Anaplastic Astrocytoma  
Medulloblastoma  
Meningioma  
Metastatic Brain Tumors  
Oligodendroglioma and Oligoastrocytoma  
Pituitary Tumors

## **FOCUSING ON TREATMENT**

Chemotherapy  
Conventional Radiation Therapy  
Stereotactic Radiosurgery  
Steroids  
Surgery  
Physician Resource List: Physicians Offering Clinical Trials for Brain Tumors

## **FOR & ABOUT CHILDREN**

Alex's Journey: The Story of a Child with a Brain Tumor (Video or DVD)  
Education Packet (Parent or Teacher)  
When Your Child Returns to School

## **SUPPORT RESOURCES**

Bibliography  
Care Options  
Emergency Alert Wallet Cards  
Employment Information  
End-of-Life Care  
Financial Aid Resources  
Health Insurance Resources  
Housing During Treatment Resources  
Net-Working Links  
Neuropsychology Resources  
Scholarship & Educational Financial Aid Resources  
Social Security Disability Resources  
Spanish-Language Resources  
Transportation Assistance Resources  
Wig and Head Covering Resources  
Wish Fulfillment Resources

## **NEWSLETTER**

Messageline Newsletter  
Sharing Knowledge, Sharing Hope e-News

## **FOCUSING ON SUPPORT**

Listing of Brain Tumor Support Groups  
Listing of Bereavement (Grief) Support Groups  
Organizing and Facilitating Support Groups  
Pen Pal Programs  
    Connections (program for patients and family members)  
    Bridges (program for those who have lost someone to a brain tumor)  
Resources for Online Support  
TLC (Tips for Living and Coping) e-bulletin

*Single copies of our publications are available free of charge.*



American Brain Tumor Association

2720 River Road, Suite 146 Des Plaines, Illinois 60018

800.886.2282 TEL info@abta.org EMAIL  
847.827.9918 FAX www.abta.org WEB



Sharing knowledge. Sharing hope.



American Brain Tumor Association

2720 River Road, Suite 146 Des Plaines, Illinois 60018

800.886.2282	TEL	<a href="mailto:info@abta.org">info@abta.org</a>	EMAIL
847.827.9918	FAX	<a href="http://www.abta.org">www.abta.org</a>	WEB